

# Baker's cysts in knees with chronic osteoarthritic pain: a clinical, ultrasonographic, radiographic and scintigraphic evaluation

Dimitrios Chatzopoulos · Efstratios Moralidis ·  
Pavlos Markou · Vassilios Makris · Georgios Arsos

Received: 26 January 2008 / Accepted: 15 June 2008  
© Springer-Verlag 2008

**Abstract** This study aimed to determine the ultrasonographic prevalence of Baker's cysts in knees with chronic osteoarthritic pain and investigate for cysts correlates and relationships with scintigraphically established synovitis. Consecutive patients with chronic osteoarthritic knee pain underwent clinical examination, X-rays, ultrasonography and early-phase bone scintigraphy. Eighty-nine Baker's cysts were detected in 328 knees with chronic osteoarthritic pain (27%), whereas one cyst was identified among the 54 non-osteoarthritic knees (2%,  $P < 0.001$ ). Baker's cysts were detected in 72/195 (37%) patients with knee osteoarthritis. Abnormal and intense tracer accumulation in early-phase bone scintigraphy were significantly more frequent in osteoarthritic knees with Baker's cysts (97 and 56%, respectively), than in those without (89 and 40%, respectively,  $P < 0.05$  for both). Clinical and radiographic variables could not predict the presence of those cysts. Baker's

cysts are a common ultrasonographic finding in knees with chronic osteoarthritic pain and are associated with synovial inflammation and its grade.

**Keywords** Baker's cyst · Bone scintigraphy · Knee · Osteoarthritis · Ultrasonography

## Introduction

Baker's cyst represents a fluid distention of a bursa between the gastrocnemius and semimembranosus tendons through a communication with the knee joint [1, 2]. In knee osteoarthritis, joint structures are biomechanically modified and may be vulnerable to the development of periarticular pathology, including synovial cysts in the popliteal region [3–5]. This knee disorder may be a frequent cause of Baker's cysts in adults, because of its high prevalence [5, 6]. However, there are few studies dealing exclusively with Baker's cysts in osteoarthritic knees and additional information may be extracted from other series investigating several features of this disorder [3, 7–11]. In previous work, not always similar criteria have been used for disease definition and a variety of exploratory methods under differing clinical settings have been employed. Thus, various aspects of Baker's cysts remain open to research, including their pathogenesis and prevalence in the course of knee osteoarthritis, and their association with symptoms and other joint changes.

Although much research focused on cartilage degradation in osteoarthritis, recent work revealed that inflammation may play a more critical role in the development and progression of the disease than once was thought [12, 13]. Since it is believed that synovitis contributes in the development of pain, limitation of movement, joint swelling and

---

D. Chatzopoulos  
Department of Nuclear Medicine, Papageorgiou Hospital,  
Thessaloniki, Greece

E. Moralidis (✉)  
Department of Nuclear Medicine, Aristotelian University,  
AHEPA Hospital, Thessaloniki, Greece  
e-mail: emoral@hol.gr; emoral@med.auth.gr

P. Markou  
Department of Medical Physics,  
Health Care Unit Management, Edessa, Greece

V. Makris  
Department of Orthopaedics, Aristotelian University,  
Papageorgiou Hospital, Thessaloniki, Greece

G. Arsos  
Department of Nuclear Medicine, Aristotelian University,  
Hippokraton Hospital, Thessaloniki, Greece

effusion in knee osteoarthritis, we hypothesized that Baker's cysts formation would also be associated with synovial inflammation. Early-phase bone scintigraphy is an accepted modality for the detection and assessment of severity of inflammation in soft-tissue joint structures [14, 15], whereas ultrasound can effectively image the popliteal region and determine the presence and characteristics of Baker's cysts [7, 8, 16, 17].

The objective of this study was twofold: (a) to determine the ultrasonographic prevalence of Baker's cysts in knees with chronic osteoarthritic pain and investigate for its correlates among clinical and radiographic variables and (b) to test our hypothesis using early-phase bone scintigraphy. For this purpose, patients attending an open access outpatient clinic for the assessment of the appropriateness of radiation synovectomy were examined.

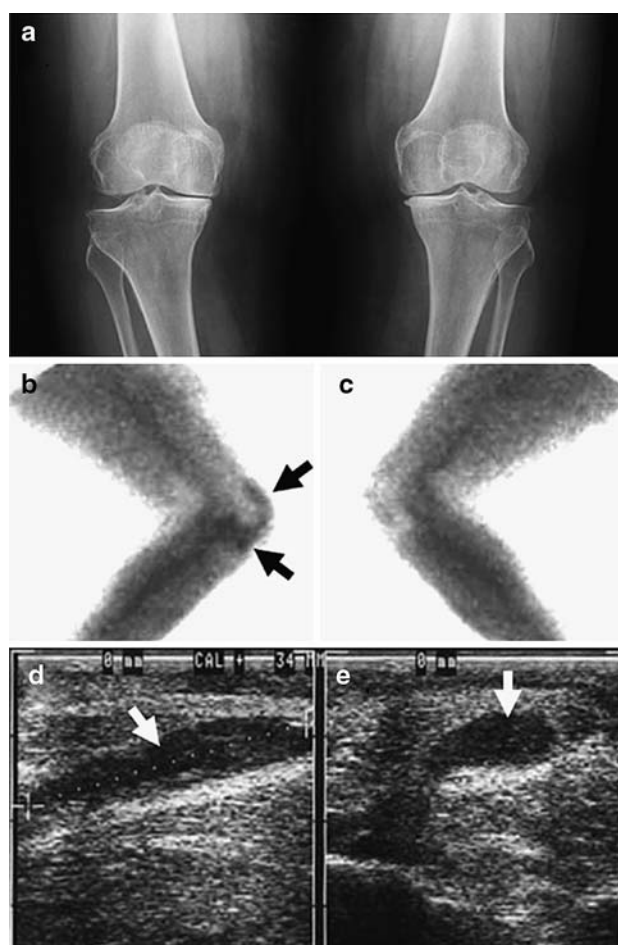
### Patients and method

Consecutive patients with a diagnosis of osteoarthritis in at least one knee, as recorded in their medical files, underwent ultrasonographic examinations of both knee joints for the investigation of Baker's cysts. These patients were complaining of chronic knee pain, inadequately controlled by systemic or local pharmacotherapy, and were attending an open access outpatient clinic for the evaluation of the appropriateness of radiation synovectomy. Apart from ultrasonography, participants were submitted also to physical examination, plain radiography and an early-phase bone scan. This array of tests is routinely applied in our facility and conforms to standard examination of patients evaluated for radiation synovectomy, in which the investigation for Baker's cysts is an essential part [15]. Typically, all examinations were carried out within the day of patients visit or in the next day. The diagnosis of knee osteoarthritis was independently confirmed, based on the criteria of the American College of Rheumatology [18]. Participants were systematically interrogated, medical records were carefully reviewed and if necessary treating physicians were contacted to ensure that no patient enrolled had any of the following characteristics: rheumatoid arthritis, a history of knee trauma, previous knee surgery, intraarticular steroid and hyaluronic acid injections within 3 months before presentation to the clinic or knee disorders secondary to infection or metabolic abnormalities.

A knee-orientated history was taken and knee discomfort in the prior month was graded using a 3-point scale: 0, no pain; 1, pain only at stress limiting daily activities (walking, climbing, weight-lifting); 2, pain at stress and rest (also including nocturnal pain). The range of motion of the knees was measured from full extension to maximum flexion using a goniometer.

All subjects underwent weight-bearing posteroanterior (Fig. 1a) and lateral plain radiography of the knees. Radiographic severity of the disease was classified according to the standard radiological Kellgren–Lawrence grading system for osteoarthritis, defined as follows [19]: 0, no signs of osteoarthritis; 1, minute osteophytes of doubtful importance; 2, definite osteophytes but preserved joint space; 3, definite osteophytes and moderate narrowing of joint space; 4, greatly impaired joint space and sclerosis of subchondral bone.

Early-phase bone scintigrams were performed after intravenous injection of 370 MBq Tc-99m-methylene-diphosphonate, using a double-headed gamma camera (Vertex Plus Epic, ADAC, CA, USA) equipped with a low



**Fig. 1** A 64-year-old woman with chronic osteoarthritic pain in both knees. Weight-bearing posteroanterior plain radiography (a) shows Kellgren–Lawrence grade 3 radiographic alterations bilaterally. Lateral blood-pool images show intense tracer accumulation in the synovium of the right knee (b, black arrows) and normal tracer accumulation in the left knee (c). In ultrasonographic examination a Baker's cyst was identified in the right knee (white arrows in d, longitudinal plane, and e, transverse plane), with its longest diameter measured 3.4 cm (crosses in d). No cyst was detected in the left popliteal region

energy, high resolution, parallel hole collimator and interfaced to a Pegasys computing system. Blood-pool images of the knees were assessed for elevated perfusion in the synovium, reflecting inflammation (Fig. 1b, c). Tracer concentration was graded visually, using a 3-point scale: 0, normal; 1, mildly abnormal (equal to the adjacent soft tissues); 2, intense tracer accumulation (more than the neighboring soft tissues).

Knee X-rays and bone scans were interpreted by two experienced independent observers, blinded to clinical and other imaging data; in cases of discrepancy a consensus reading was obtained.

At the time of clinical appointment, patients underwent real-time ultrasonography in the supine position with legs flexed at 30°–40°, for the evaluation of knee joints. The presence and amount of joint effusion was assessed from scans through the suprapatellar recess and measurement of its maximum anteroposterior width [8]. Knee joint effusion was classified as absent (<2 mm), small (2–5 mm) and large (>5 mm). Then, ultrasound examination was performed with the patient in prone position and knees in extension, starting at the dorsal and medial aspect of the knee joint, in the transverse plane. The presence of Baker's cysts was based on hypoechoic, anechoic or mixed echolucency appearances between the semimembranosus and medial gastrocnemius tendons. The examination was completed by imaging of the Baker's cyst in the longitudinal plane to determine the shape and cephalocaudal extent. Subsequently, its longest dimension was measured twice and the mean value was entered in analysis (Fig. 1d, e). All ultrasonographic examinations were performed by a trained and experienced physician, using a 7.5-MHz linear-array transducer and standard settings of the device (UM4A, ATL, Washington, USA).

Knee joints were separated into three groups. The control group consisted of knees not fulfilling the criteria of osteoarthritis and no other specific joint disease determined. Knees with chronic osteoarthritic pain were encompassed into two different groups, according to the presence or absence of a Baker's cyst.

### Statistical analysis

Continuous variables are presented as mean  $\pm$  1 standard deviation or as median and range and categorical variables as numbers or proportions. In the comparison of categorical data the chi-square test, including Yates continuity correction when appropriate, and Fischer's exact test were used, with Bonferoni's adjustment applied for multiple paired comparisons. Continuous variables were compared by the Mann–Whitney rank sum test or the Kruskal–Wallis statistic; the latter was followed by Dunn's formula for paired

comparisons. The values of the diagnostic performance of tests (sensitivity, specificity, etc.) are quoted as point estimate (95% confidence intervals). A *P* value < 0.05 was considered statistically significant.

### Results

One-hundred and ninety-six patients (49 male), aged  $69 \pm 9$  years (range 49–87), were enrolled. Ten patients (three male) had a previous unilateral knee arthroplasty (five right-sided and five left-sided) and these knee joints were excluded by entry criteria. Among the remaining 382 knee joints 90 Baker's cysts were detected in 72 patients. Cysts had an elongated, crescent or ovoid shape and their longest diameter invariably was in the superior-inferior plane, measured  $4.0 \pm 1.1$  cm (range 1.4–6.2). In all cases a narrow neck connecting the cyst and the posterior joint capsule could be visualized, whereas no findings of leak or rupture were noted.

The control group consisted of 54 non-osteoarthritic knees from 54 patients. A Baker's cyst was detected among those knees which is equal to a frequency of 2%. A clinical diagnosis of osteoarthritis was established in 328 knees from 195 patients (in 133 patients both knees were affected). The median duration of symptoms was 48 months (range 3 months–8 years). In 120 knee joints (37%) discomfort had started no longer than 2 years ago and in 112 knees (34%) the onset of complaints dated back to at least 6 years. Eighty-nine Baker's cysts were identified in the knees with chronic osteoarthritic pain, providing a prevalence of 27% ( $P < 0.001$ , in comparison to the control group). Those cysts were detected in 72 patients (in 55 unilaterally and in 17 bilaterally), providing a prevalence of 37% on a per-patient basis and a frequency of 9% for patients with bilateral cysts.

The characteristics of patients with chronic osteoarthritic knee pain, separated into those with and those without a Baker's cyst, together with the features of patients with unilateral versus bilateral cysts are listed in Table 1. As inferred from that table, there was no statistically significant difference in the prevalence of Baker's cysts between male [20/49 (41%)] and female [52/146 (36%)] patients with chronic osteoarthritic knee pain. However, among patients with Baker's cysts, the frequency of subjects with bilateral cysts was significantly higher in men [9/20 (45%)] than in women [8/52 (15%),  $P < 0.02$ ].

The features of the 54 knee joints from the control group and those of the 328 knees with chronic osteoarthritic pain, with or without a Baker's cyst, are presented in Table 2. When separately comparing the control group with either group of osteoarthritic knees (with or without Baker's cysts) significant differences were found in side, range of

**Table 1** Characteristics of patients with chronic osteoarthritic knee pain

	Patients with no Baker's cysts ( <i>n</i> = 123)	Patients with Baker's cysts ( <i>n</i> = 72)	<i>P</i>	Patients with unilateral Baker's cysts ( <i>n</i> = 55)	Patients with bilateral Baker's cysts ( <i>n</i> = 17)	<i>P</i>
Age (years)	69 ± 9	70 ± 9	ns	69 ± 9	73 ± 8	ns
≥70 yrs, <i>n</i> (%)	64 (52%)	38 (53%)	ns	27 (49%)	11 (65%)	ns
Male, <i>n</i> (%)	29 (24%)	20 (28%)	ns	11 (20%)	9 (53%)	<0.05
Female, <i>n</i> (%)	94 (76%)	52 (72%)	ns	44 (80%)	8 (47%)	<0.05

ns Non-significant

**Table 2** Characteristics of the 382 knee joints classified into the 3 defined groups

	Control group ( <i>n</i> = 54)	Groups of osteoarthritic knees		<i>P</i> *	<i>P</i> **
		Baker's cyst absent ( <i>n</i> = 239)	Baker's cyst present ( <i>n</i> = 89)		
Left/right knee, <i>n</i>	36/18	118/121	37/52	<0.05	ns
Pain at stress, <i>n</i> (%)	0	97 (41%)	29 (33%)	<0.001	ns
Pain at stress and rest, <i>n</i> (%)	0	142 (59%)	60 (67%)	<0.001	ns
Duration of pain (mo)	0	47 ± 28	45 ± 29	<0.001	ns
Range of motion (degrees)	127 ± 4	116 ± 18	117 ± 15	<0.001	ns
K-L <sup>a</sup> 0, <i>n</i> (%)	16 (29%)	16 (7%)	4 (5%)	<0.001	ns
K-L 1, <i>n</i> (%)	28 (52%)	58 (24%)	20 (22%)	<0.001	ns
K-L 2, <i>n</i> (%)	9 (17%)	73 (31%)	30 (34%)	<0.001	ns
K-L 3, <i>n</i> (%)	1 (2%)	74 (31%)	25 (28%)	<0.001	ns
K-L 4, <i>n</i> (%)	0	18 (7%)	10 (11%)	<0.001	ns
Abnormal early-phase bone scan, <i>n</i> (%)	13 (24%)	212 (89%)	86 (97%)	<0.001	<0.05
Intense synovial tracer accumulation in an early-phase bone scan, <i>n</i> (%)	0	95 (40%)	50 (56%)	<0.001	<0.05
Joint effusion, <i>n</i> (%)	15 (28%)	229 (96%)	88 (99%)	<0.001	ns
Large effusion, <i>n</i> (%)	1 (2%)	63 (26%)	27 (30%)	<0.001	ns

In paired comparisons between all osteoarthritic knees (as a single group) and those in the control group a significant difference was found in all variables, with *P* < 0.05 for the side of the knee and *P* < 0.001 for the rest

ns Non-significant

\* Comparison of all groups together; \*\*paired comparisons between the two groups of osteoarthritic knees

<sup>a</sup> K–L, Kellgren–Lawrence radiographic grade

motion, the presence and severity of X-ray changes, the abnormal appearance and degree of tracer accumulation in early-phase bone scans, and the presence and amount of joint effusion. In the discrimination of Baker's cysts in knees with chronic osteoarthritic pain an abnormal early-phase bone scintigraphy provided a sensitivity of 0.97 (0.96–0.98), a specificity of 0.11 (0.10–0.13) and positive and negative predictive values of 0.29 (0.23–0.34) and 0.90 (0.79–1.0), respectively. The corresponding values provided by an intense tracer accumulation pattern in blood-pool bone scanning were 0.56 (0.46–0.66), 0.60 (0.54–0.66), 0.34 (0.26–0.42) and 0.79 (0.73–0.85).

In knees with chronic osteoarthritic pain the longest diameter of Baker's cysts did not differ significantly between those with a large joint effusion (4.2 ± 0.9 cm) and those with a small one (3.9 ± 1.1 cm).

## Discussion

This study shows that Baker's cysts are a common ultrasonographic finding in patients with chronic osteoarthritic knee pain, with a prevalence of 27% among affected knees and 37% on a per-patient basis. Bilateral cysts were found in 9% of patients with osteoarthritis and these were more frequent in men than women. Among all clinical, radiographic, ultrasonographic and scintigraphic variables, only an abnormal early-phase bone scan and intense tracer accumulation in the synovium were significantly more frequent in osteoarthritic knees with Baker's cysts in comparison to those without.

A considerably variable prevalence of Baker's cysts has been reported previously, depending on the imaging modality and the population studied [1, 6, 17, 20, 21]. In series of

patients at least 45-year-old with knee osteoarthritis the prevalence of Baker's cysts by Magnetic Resonance Imaging (MRI) ranged from 33 to 47% [3, 8–10]. In osteoarthritic knees evaluated by ultrasonography frequencies of 22.2, 29 and 35% for Baker's cysts have been found [7, 8, 16]. The per-patient prevalence of Baker's cysts in knee osteoarthritis by ultrasound was 35 and 42% in earlier work [7, 8] and the frequency of patients with bilateral cysts was 16% [7].

There was a very low frequency (2%) of Baker's cysts in non-osteoarthritic knees in our study. This finding is concordant with previous ultrasonographic data [13], but our frequency is smaller than that of other series using MRI or ultrasound [3, 4, 9, 11, 22]. The reason for this discrepancy is unclear, but since ultrasound offers an accuracy comparable to that of MRI [8, 17, 23], differences in patient selection and a higher clinical threshold in ordering MRI studies of the knees would account for this situation.

In our sample, the prevalence of Baker's cysts was not affected by age, gender, the duration of symptoms or the impairment in knee flexibility (Tables 1 and 2). The general increase in Baker's cyst incidence with age may not apply in knees with osteoarthritis, which is primarily a disease of the elderly [1, 5]. In a previous study in knee osteoarthritis, the reported range of size of those cysts by ultrasonography (0.5–4 cm) indicates smaller dimensions than those in our group (1.4–6.2 cm) [7]. In our cohort there was no difference in the frequency of Baker's cysts according to the side of disease. Moreover, the severity of pain could not discriminate between the presence and absence of Baker's cysts in our osteoarthritic knees (Table 2). In knees with degenerative lesions on X-rays, associations between pain and Baker's cysts have been described previously [9, 16], although other investigators support the opposite [3, 10]. Furthermore, in our study the prevalence of Baker's cysts did not differ according to the presence and severity of radiographic abnormalities of the osteoarthritic joints, which is discordant to other publications [4, 7]. In substantial agreement with earlier reports, knee effusions were detected almost invariably in our sample of osteoarthritic knees, and thus they could not alter the likelihood of Baker cysts, even if they were large (Table 2) [8, 9, 16]. In addition, the amount of joint effusion was not related to the size of the cysts. These observations are in accordance with previous arthrographic data but incongruous to other work using MRI [24]. Overall, our findings cannot explain the development of Baker's cysts by intraarticular fluid accumulation alone, but it is likely that their formation is moderated by other mechanisms, such as the patency status of the interconnection between the joint and the bursa and the intrinsic features of joint capsule [1, 6, 23].

Unlike previous work in the field, in our study joint inflammation was investigated and identified by early-

phase bone scans (Fig. 1b). Moreover, the degree of inflammation in osteoarthritis may vary from a mild intermittent irritation to marked synovitis, and hence the assessment of the intensity of tracer accumulation in the synovium has obvious appeal [25]. Early-phase bone scintigraphy could discriminate between osteoarthritic and non-osteoarthritic knees, with an abnormally elevated synovial perfusion being significantly more frequent in osteoarthritic knees with Baker's cysts than in those without (Table 2). Similar were the findings on the frequency of Baker's cysts according to the intensity of synovial tracer accumulation in blood-pool images. These observations suggest that the presence of Baker's cysts in knees with chronic osteoarthritic pain is associated with synovial inflammation and its grade. This, in turn, indicates that the development of Baker's cysts may be stimulated or mediated by synovitis. The resolution of those cysts after intraarticular yttrium-90 treatment of the inflamed synovium in knee osteoarthritis also reinforces that notion [26]. It should be emphasized, however, that Baker's cysts are present in only a fraction of knees with chronic osteoarthritic pain and scintigraphic evidence of synovitis, possibly because their formation also depends on other factors. Thus, in the scintigraphic examination of osteoarthritic knees only a negative early-phase result may be clinically meaningful (negative predictive value 90%), as it indicates a remote probability for Baker's cysts. Conversely, an abnormal blood-pool scan is an inadequate predictor of the presence of those cysts (positive predictive value 29%). In this context, the values of the diagnostic performance of an intense tracer accumulation pattern in early-phase bone scintigraphy also imply that this variable would not be particularly helpful.

#### Potential limitations of the study

The control sample consisted of painless knees from patients with contralateral knee osteoarthritis, in an effort to match for joints considered under the closest possible clinical setting. Although this is not the best possible control group, submitting to the above mentioned array of examinations, including scintigraphy with appreciable radiation exposure, healthy volunteers or different people with no knee discomfort would be impractical and potentially unethical. On the other hand, in our sample various intervals of duration of symptoms, patterns of disease and degrees of radiographic damage were represented in reasonable proportions.

The acquisition of the ultrasonographic data is highly operator dependent. However, an excellent inter-observer agreement has been shown in the assessment of knee pathology with ultrasound, including Baker's cysts [27], and all examinations were performed by the same physician, having more than 10 years of experience.

## Conclusions

Baker's cysts are a common ultrasonographic finding in knees with chronic osteoarthritic pain and are associated with synovial inflammation in the joint and its grade, as demonstrated by early-phase bone scintigraphy. Clinical variables, radiographic damage and knee joint effusions cannot predict the presence of Baker's cysts in those knees.

## References

- Handy JR (2001) Popliteal cysts in adults: a review. *Semin Arthritis Rheum* 31:108–118. doi:10.1053/sarh.2001.27659
- Fritschy D, Fasel J, Imbert J-C, Bianchi S, Verdonk R, Wirth CJ (2006) The popliteal cyst. *Knee Surg Sports Traumatol Arthrosc* 14:623–628. doi:10.1007/s00167-005-0028-z
- Hill CL, Gale DG, Chaisson CE, Skinner K, Kazis L, Gale ME et al (2001) Knee effusions, popliteal cysts and synovial thickening: association with knee pain in osteoarthritis. *J Rheumatol* 28:1330–1337
- Hill CL, Gale DR, Chaisson CE, Skinner K, Kazis L, Gale ME et al (2003) Periarticular lesions detected on magnetic resonance imaging. Prevalence in knees with and without symptoms. *Arthritis Rheum* 48:2836–2844. doi:10.1002/art.11254
- Felson DT (2006) Osteoarthritis of the knee. *N Engl J Med* 354:841–848. doi:10.1056/NEJMc051726
- Miller TT, Staron RB, Koenigsberg T, Levin TL, Feldman F (1996) MR imaging of Baker cysts: association with internal derangement, effusion and degenerative arthropathy. *Radiology* 201:247–250
- Fam AG, Wilson SR, Holmberg S (1982) Ultrasound evaluation of popliteal cysts on osteoarthritis of the knee. *J Rheumatol* 9:428–434
- Tarhan S, Unlu Z, Goktan C (2003) Magnetic resonance imaging and ultrasonographic evaluation of the patients with knee osteoarthritis: a comparative study. *Clin Rheumatol* 22:181–188. doi:10.1007/s10067-002-0694-x
- de Miguel Mendieta E, Cobo Ibanez T, Uson Jaeger J, Bonilla Hernan G, Martin Mola E (2006) Clinical and ultrasonographic findings related to knee pain in osteoarthritis. *Osteoarthr Cartil* 14:540–544. doi:10.1016/j.joca.2005.12.012
- Kornaat PR, Bloem JL, Ceulemans RYT, Riyazi N, Rosendaal FR, Nelissen RG et al (2006) Osteoarthritis of the knee: association between clinical features and MR imaging findings. *Radiology* 239:811–817. doi:10.1148/radiol.2393050253
- Phan CM, Link TM, Blumenkrantz G, Dunn TC, Ries MD, Steinbach LS et al (2006) MR imaging findings in the follow-up of patients with different stages of knee osteoarthritis and the correlation with clinical symptoms. *Eur Radiol* 16:608–618. doi:10.1007/s00330-005-0004-5
- Hedbom E, Hauselmann HJ (2002) Molecular aspects of pathogenesis in osteoarthritis: the role of inflammation. *Cell Mol Life Sci* 59:45–53. doi:10.1007/s00018-002-8404-z
- Pearle AD, Scanzello CR, George S, Mandl LA, DiCarlo EF, Peterson M et al (2007) Elevated high-sensitivity C-reactive protein levels are associated with local inflammatory findings in patients with osteoarthritis. *Osteoarthr Cartil* 15:516–523. doi:10.1016/j.joca.2006.10.010
- Colamussi P, Prandini N, Cittanti C, Feggi L, Giganti M (2004) Scintigraphy in rheumatic diseases. *Best Pract Res Clin Rheumatol* 18:909–926. doi:10.1016/j.berh.2004.07.003
- Fischer M, Mödder G (2002) Radionuclide therapy of inflammatory joint disease. *Nucl Med Commun* 23:829–831. doi:10.1097/00006231-200209000-00003
- Naredo E, Cabero F, Palop MJ, Collado P, Cruz A, Crespo M (2005) Ultrasonographic findings in knee osteoarthritis: a comparative study with clinical and radiographic assessment. *Osteoarthr Cartil* 13:568–574. doi:10.1016/j.joca.2005.02.008
- Ward EE, Jacobson JA, Fessell DP, Hayes CW, van Holsbeeck M (2001) Sonographic detection of Baker's cysts: comparison with MR imaging. *AJR Am J Roentgenol* 176:373–380
- Altman R, Asch E, Bloch D, Bole G, Borenstein D, Brandt K et al (1986) The American College of Rheumatology criteria for the classification and reporting of osteoarthritis of the knee. *Arthritis Rheum* 29:1039–1049. doi:10.1002/art.1780290816
- Kellgren J, Lawrence J (1957) Radiological assessment of osteoarthritis. *Ann Rheum Dis* 16:494–501
- Hermann G, Yeh HC, Lehr-Janus C, Berson BL (1981) Diagnosis of popliteal cyst: double contrast arthrography and sonography. *AJR Am J Roentgenol* 137:369–372
- Sansone V, De Ponti A, Paluella GM, Del Maschio A (1995) Popliteal cysts and associated disorders of the knee. Critical review with MRT imaging. *Int Orthop* 19:275–279. doi:10.1007/BF00181107
- Tschirch FTC, Schmid MR, Pfirrmann CWA, Romero J, Hodler J, Zanetti M (2003) Prevalence and size of meniscal cysts, ganglionic cysts, synovial cysts of the popliteal space, fluid-filled bursae, and other fluid collections in asymptomatic knees on MR imaging. *AJR Am J Roentgenol* 180:1431–1436
- Torreggiani WC, Al-Ismail K, Munk PL, Roche C, Keogh C, Nicolaou S et al (2002) The imaging spectrum of Baker's (popliteal) cysts. *Clin Radiol* 57:681–691. doi:10.1053/crad.2001.0917
- Johnson LL, van Dyk GE, Johnson CA, Bays BM, Gylly SM (1997) The popliteal bursa (Baker's cyst): an arthroscopic perspective and the epidemiology. *Arthroscopy* 13:66–72. doi:10.1016/S0749-8063(97)90211-5
- Goldenberg DL, Egan MS, Cohen AS (1982) Inflammatory synovitis in degenerative joint disease. *J Rheumatol* 9:204–209
- Chatzopoulos D, Moraliadis E, Pavlou M, Makris V (2008) Yttrium-90 radiation synovectomy in knee osteoarthritis: a prospective assessment at 6 and 12 months. *Nucl Med Commun* (in press).
- Scheel AK, Schmidt WA, Hermann K-GA, Bruyn GA, D'Agostino MA, Grassi W et al (2005) Interobserver reliability of rheumatologists performing musculoskeletal ultrasonography: results from a EULAR "Train the trainers" course. *Ann Rheum Dis* 64:1043–1049. doi:10.1136/ard.2004.030387